

PATIENT PRESENTING CLINICAL SIGNS

Draco Lawson

History: Worsening 3/6 systolic murmur

SPECIES ECHOCARDIOGRAPHIC FINDINGS

Feline

2D, M-mode, and Doppler study.

BREED

Left atrial size is normal. The mitral valve appears normal, though mild mitral regurgitation is present. There is borderline mild left ventricular hypertrophy. Left ventricular internal dimensions are normal. Left ventricular systolic function is hyperdynamic. The aorta and aortic valve appear normal, though there is mildly increased flow velocity in the ascending aorta. Right atrial and right ventricular dimensions are normal. The tricuspid valve appears normal. The pulmonary artery and pulmonic valve are normal. No shunting lesions are visualized. No pericardial effusion or cardiac masses are seen.

DSH

SEX

Male Neutered

AGE

2 years

WEIGHT

7.9#

LA/Ao - 1.24
IVSd - 5.6 mm
LVPWd - 5.6 mm
LVIDd - 11.0 mm
LVIDs - 4.0 mm
FS - 63.6%
LVOT - 1.58 m/s
RVOT - 1.46 m/s

INTERPRETED BY

Keith Blass, DVM,
MS, DACVIM

ASSESSMENT/RECOMMENDATIONS

This examination demonstrates mild regurgitation of blood across Draco's mitral valve disease, as well as borderline mild hypertrophy of his left ventricular walls. While Draco's wall thickness does not meet the definitive criterion of 6 millimeters to diagnose hypertrophic cardiomyopathy (HCM), some cats with wall thicknesses above 5.5 millimeters will be affected with the disease, therefore, its presence cannot be ruled out. In any case, the hemodynamic effects of Draco's mitral regurgitation and borderline LV hypertrophy are mild at present, as he does not have secondary dilation of his left atrium, indicating that his current risk for the development of congestive heart failure and/or cardiac thrombus formation appears to be low.

IMAGING PERFORMED BY

Rebekah Jakum, CVT
ARDMS/RVT

No therapy is recommended based on this exam.

HOSPITAL NAME

Littlestown VH

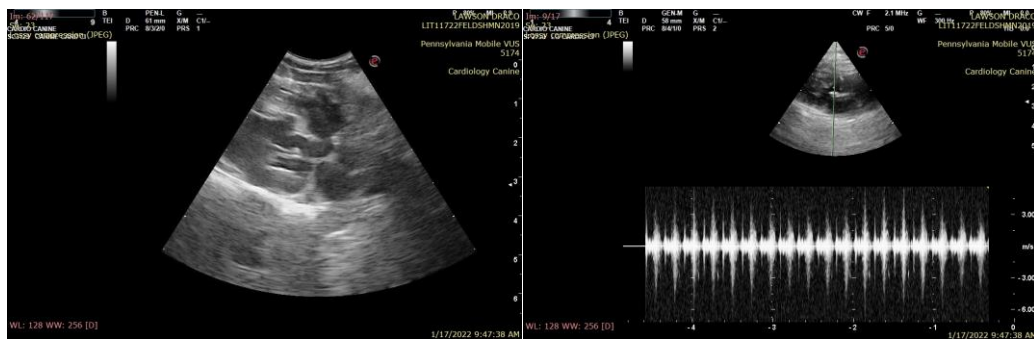A recheck echocardiogram is recommended in 6-9 months, sooner if new clinical signs compatible with cardiac dysfunction develop.

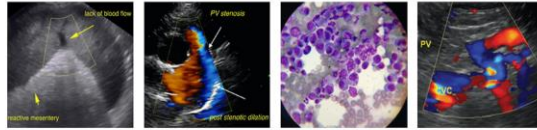
REFERRING VET

Dr. Kubala

DATE

1.17.2022





PATIENT

Draco Lawson

The information and recommendations provided are based on the images presented by the referring veterinarian. No evaluation can be communicated regarding pathology that was not visible in the image/video clips provided.

SPECIES

Feline

Thank you for this referral. If the clinical or image interpretation does not parallel your findings or if I can be of any further assistance please contact me.

BREED

DSH

Keith Blass, DVM, MS, DACVIM (Cardiology)

KeithBlass@gmail.com

631-804-5754

SEX

Male Neutered

AGE

2 years

WEIGHT

7.9#

INTERPRETED BY

Keith Blass, DVM,
MS, DACVIM

**IMAGING
PERFORMED BY**

Rebekah Jakum, CVT
ARDMS/RVT

HOSPITAL NAME

Littlestown VH

REFERRING VET

Dr. Kubala

DATE

1.17.2022